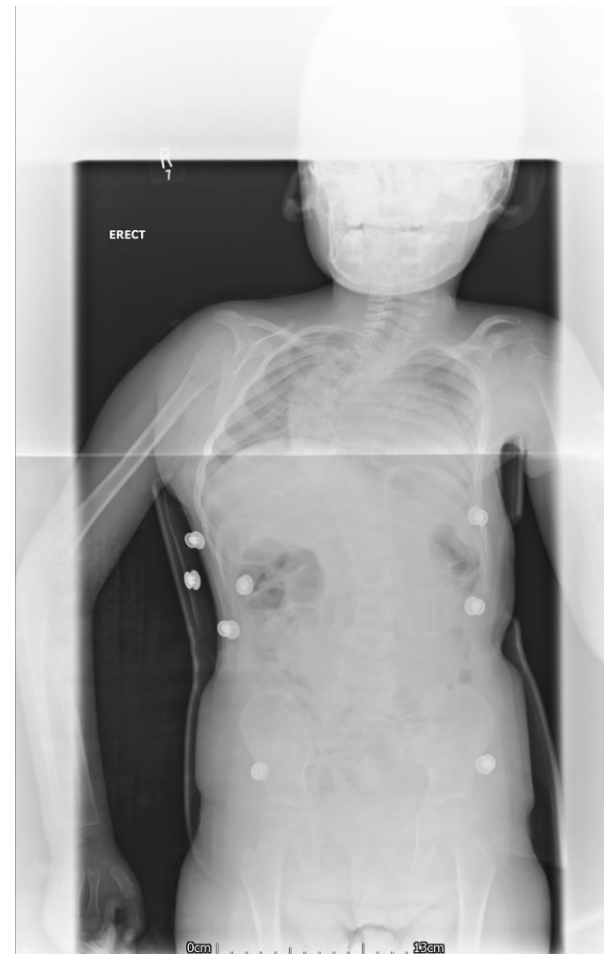

Avoiding complications

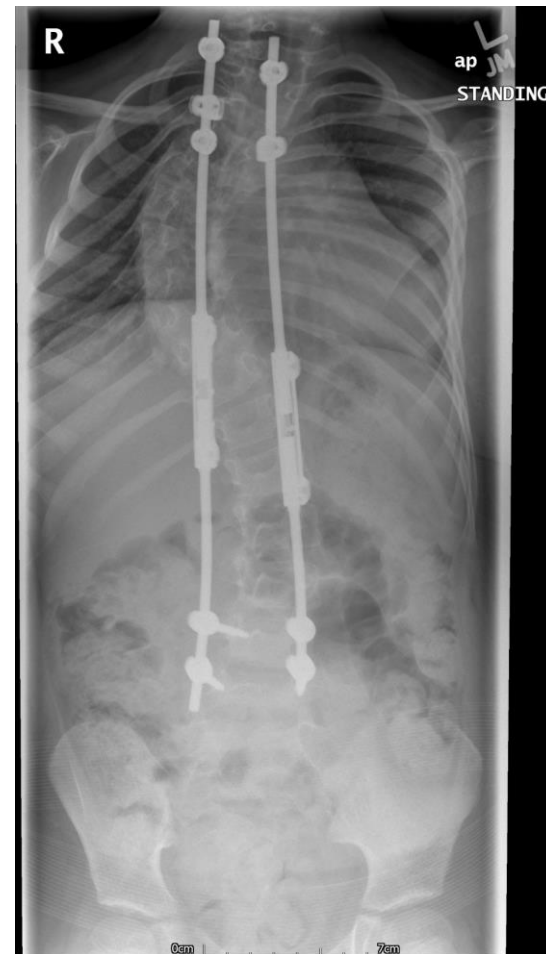Colin Nnadi

Oxford University Hospitals UK

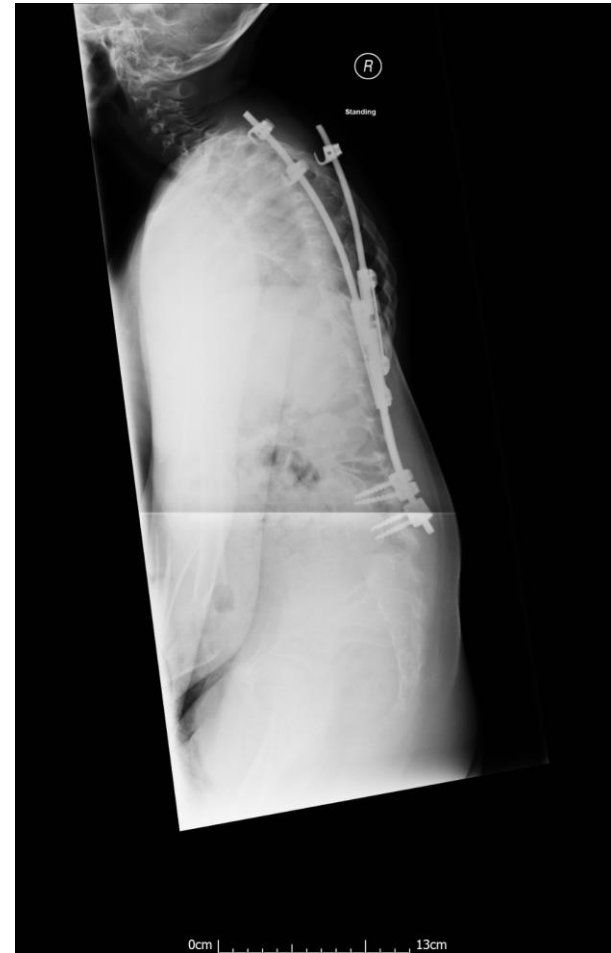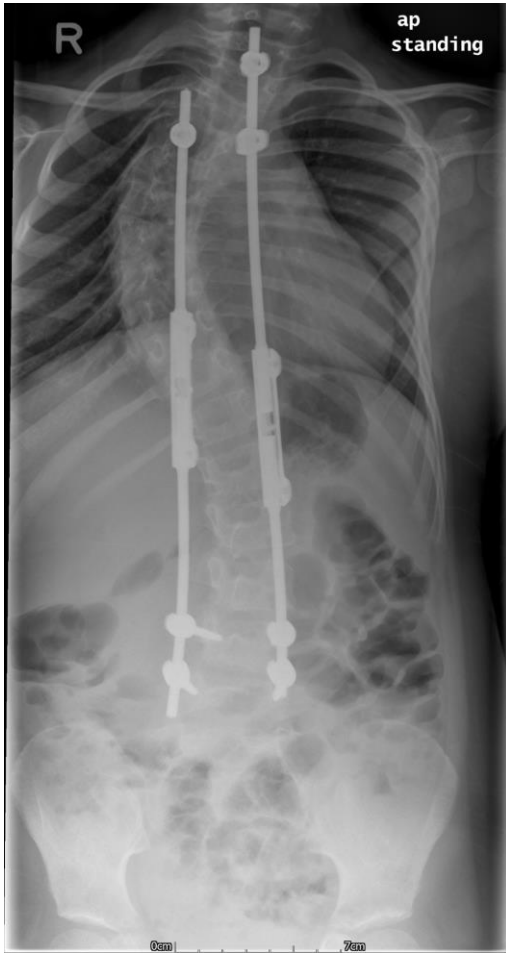
- 11 M
- EOS
- Prader Willi syndrome diagnosed at 17 mnths
- Developmental delay
- Growth Hormone Therapy
- GORD
- Recurrent URTI's



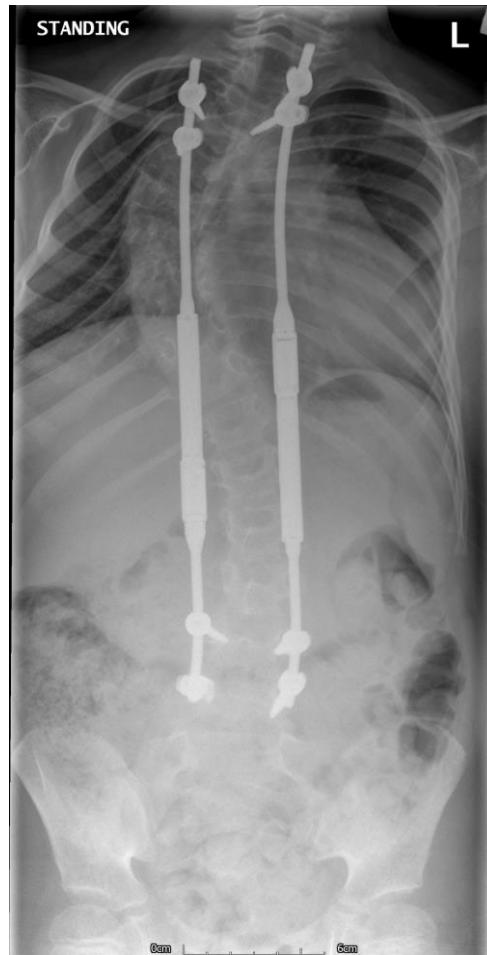- Serial casting May 2006 – June 2008
- Cobb initially 44° rising to 51°
- March 11 Cobb 73°
- Nov 11 TGR



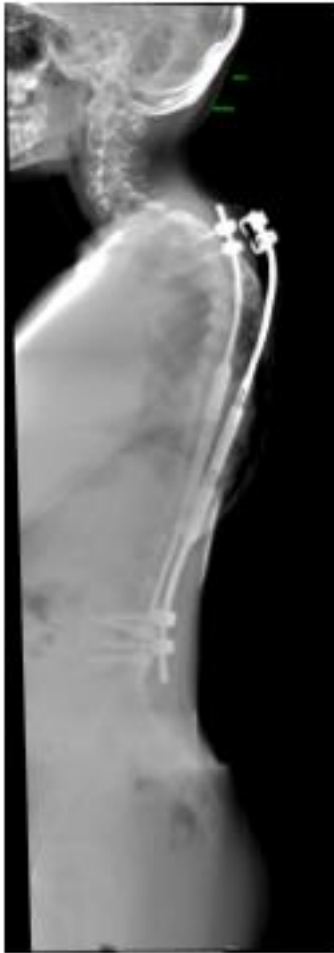January 2012



February 2012

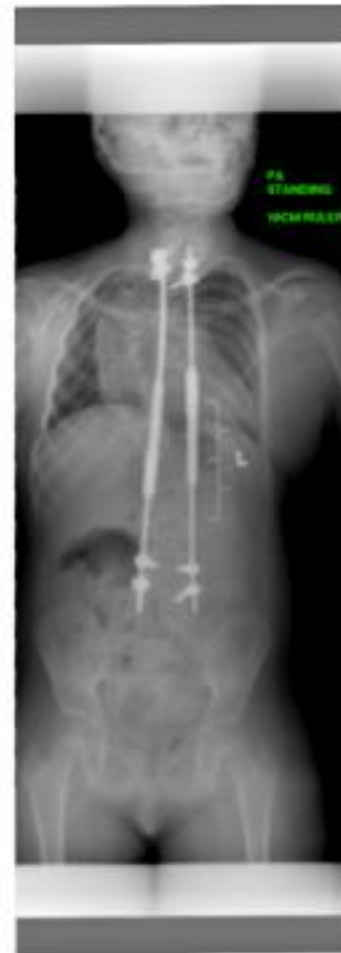

- Jan 2014 – ED with pain & redness over Rt prox anchors
- Redness improved over 1 week
- Feb 2014 – discharge from top wound. USS shows collection
- Washout and trimming of rod
- MCS no organisms isolated

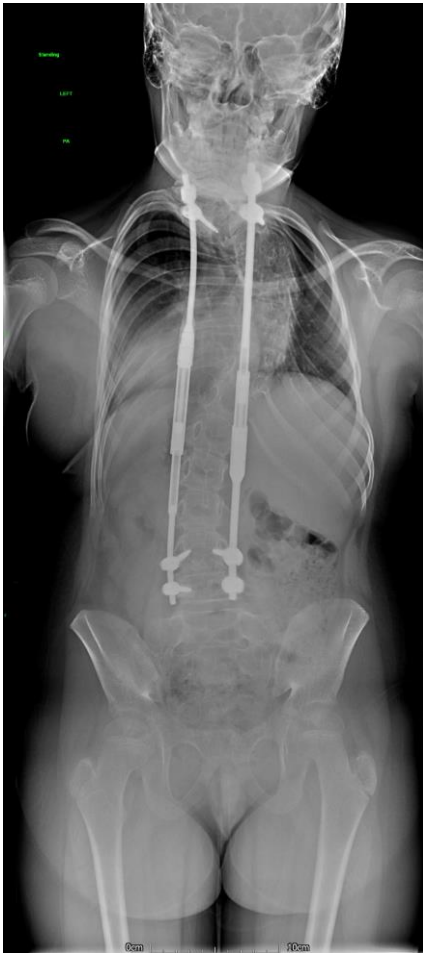

- March 2014 Rt proximal anchors loose
- Listed for revision surgery
- Wound breakdown April 2014. Staph A isolated

- Revision surgery June 2014
- Coag –ve Staph
- Antibiotics x 6 mnths
- No further problems

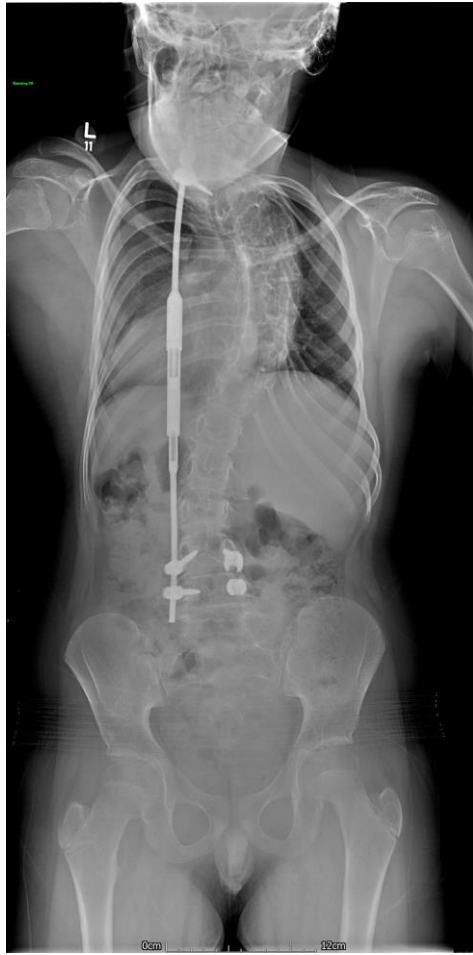


September 2015



- Lt rod reaches limit
- Nov 2015 – left rod revised
- Nov 2015 – Infection
- Staph A isolated
- Wound washout

- March 2016 – pain over Rt proximal anchors again
- August 2016 – Revision surgery for infection
- October 2016 – Rt proximal anchors detached again



SUMMARY

- 6 operations including conversion from TGR
- Deep infection
- 2 MCGR rod exchanges
- 1 MCGR removal

Multiple theatre episodes

Infection

Costs

What would I do differently?

- Patient selection
- Patient selection
- Patient selection